

# One Case of Internal Fixation Treatment for Tibia and Fibula Fracture of Dogs

Chunhui XU<sup>1</sup>, Yong TAO<sup>2\*</sup>

\*Jiangsu Agri-animal Husbandry Vocational College, China, Jiangsu, Taizhou

**Abstract**— *Tibia and fibula fracture is a common fracture of hind limb in dogs. It is caused by external force on the hind limb. After fracture happens, external fixation is often used for treatment, and the effect is ideal. However, if the fracture site is close to the joint, we suggest to use internal fixation as far as possible, so as not to cause sequelae of joint stiffness. The author diagnosed the fracture of tibia and fibula in the left hind limb of the poodle through combining the incidence, clinical manifestations and DR examination, and then used the internal fixation plate for internal fixation. Under postoperative care, the dog recovered well.*

**Keywords**— *fracture, tibia and fibula, internal fixation, internal fixation plate.*

## I. INTRODUCTION

Fracture refers to the bone state in which the integrity or continuity of bone tissue is destroyed by external force or pathological factors. Fracture is accompanied with different degrees of injury of soft tissue around the bone [1]. Most fractures occur in limb bones, which are caused by external injuries, that is, direct external violence, such as vehicle collision, trampling, rolling, falling, hammering and squashing. Fractures may also be caused by strong contraction of muscles such as running, twisting and sudden stop. For tibia and fibula fracture, we usually use external fixation in clinic, but if the fracture site is close to the joint, it is easy to cause dead joint, and in this case, we mostly use internal fixation. The author diagnosed and treated a case of tibia and fibula fracture caused by traffic accident. After using the internal fixation plate to carry out internal fixation, the effect was good.

## II. INCIDENCE

Poodle, 9 months old, male, 3.4 kg. Hit by the battery car, after which its left hind limb could not touch the ground. There was obvious hematoma in some part of the distal end of tibia and fibula, and dislocated movement appeared. When the swelling part moves up and down, bone fricative sound can be heard. When the dog walking, it showed supporting limb lameness. Once the dog the left hind limb was touched, the dog barked in pain.

## III. CLINICAL DIAGNOSIS

After the preliminary clinical diagnosis, the dog was diagnosed with fracture. In order to further clarify the location and condition of the fracture, we examined it by X-ray. Through the blood routine index examination and the blood biochemical index examination, we judged whether we could perform an operation for the dog normally.

### 3.1 Blood routine index examination

The number of white blood cells increased, indicating that there is inflammation in the body of the dog, so we need to carry out infusion for the dog for anti-inflammatory. Mean corpuscular hemoglobin concentration decreased, indicating that there was a mild anemia. The test results of other items were in the normal range. There was no effect on the operation.

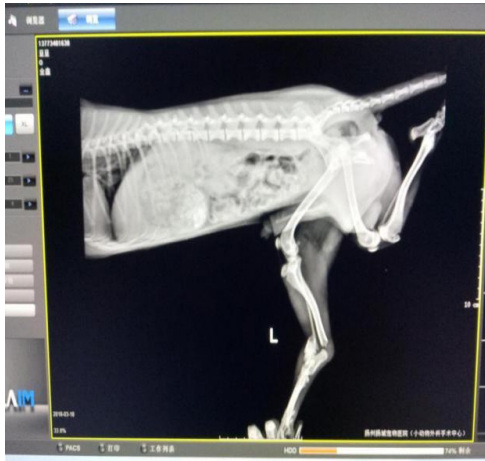
### 3.2 Blood biochemical index examination

In the biochemical examination items, except for glucose (GLU) index, which decreased, the results of all the other items were normal. GLU decrease is often due to malnutrition, dyspepsia and chronic anemia, which has no effect on the operation.

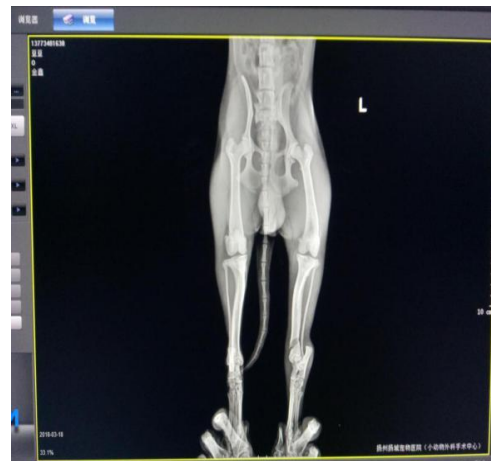### 3.3 Digital Radiography (DR) examination

DR examination: it can be seen from Figure 1 and Figure 2 that the tibia and fibula of the left hind limb is fractured. Because the fracture site is close to the joint, the operation is difficult and it was preliminarily assessed that the operation risk was high. After discussing with the owner of the dog, we finally decided the operation plan. We decided to let the dog be hospitalized for observation for 3 days, and we would first carry out routine infusion to relieve inflammation and pain. Three

days later, we performed internal fixation with internal fixation plate to treat the tibia of the dog. The fibula does not need to be treated.



**FIGURE 1: Preoperative lateral position**



**FIGURE 2: Preoperative anteroposterior**

#### IV. OPERATIVE TREATMENT

##### 4.1 Preoperative preparation

After the examination was completed, an indwelling needle was given into the dog first to facilitate the fluid infusion for the dog during the 3-day observation before the operation. It was used for anti-inflammatory, pain relief (hypodermic injection of 0.4ml tilidine), hemostasis (0.6ml etamsylate) and infusion.

**Antiphlogistic:** 30ml 0.9% NaCl injection, 2ml ceftiofur, 30ml Metronidazole and sodium chloride injection.

**Nutrient solution:** 30ml 5% glucose injection, respectively 0.6ml (0.2ml/kg) of ATP-COA (adenosine triphosphate, coenzyme A for injection) and Vc, 0.6ml (0.2ml/kg) of ethylphenesulfonate injection.

**Routine surgical instruments disinfection:** Before the operation, the dogs were forbidden to eat for 12 hours and drink water for more than 3 hours.

##### 4.2 Anesthesia

Ten minutes before the operation, the dogs were subcutaneously injected with 0.45 ml sedative drugs (0.1 ml/kg atropine sulfate and 0.05 ml/kg scepromazine) and 0.6 ml ethamsylate (0.2 ml/kg), 10 minutes later, inject 15 mg propofol slowly, which was used for induction anesthesia then we conducted endotracheal intubation and connected it to the ventilator and anesthesia machine, and then isoflurane was used to maintain the anesthesia during the operation; and then we injected 2 ml 2% lidocaine hydrochloride into different points around the operation site for local anesthesia. After connecting the ventilator and anesthesia machine, let the dog lie on the right side and fix it. Control the amount of oxygen and anesthesia, if the dog has signs of recovery during the operation, we should increase the amount of anesthesia as appropriate.

##### 4.3 Treatment of the operative site

After anesthesia, we shaved the operative site and the whole left hind limb and cleaned it up and then used clean gauze to wipe dry the affected limb. Then we used 75% alcohol cotton to disinfect the operative site in a spiral way (from inside to outside) and then used iodophor cotton to disinfect the left hind limb for 2-5 minutes. Before operation, we used 75% alcohol for deiodination and disinfection.

##### 4.4 Operation process

###### 4.4.1 Before operation

The operator should first wear sterile gloves, and then wear sterile surgical gown, masks and hats. Then open the instrument set. After disinfecting the affected limb wholly, use iodophor cotton to pinch its toe, and then the operator takes out the sterilized self-adhesive bandage from the instrument set, and uses the self-adhesive bandage to wrap the distal end of the hind limb, and then lay the operation towel well.

#### 4.4.2 During operation

First, make a skin incision parallel to the tibia on the anteromedial side of the tibia, separate the subcutaneous connective tissue and separate the fascia on the surface of the bone (Fig. 3). In the process of operation, the operator should pay attention to avoid the saphenous nerve and blood vessels in the middle and lower parts. If there is bleeding, use hemostatic forceps to clamp the blood vessels in the bleeding site to stop bleeding. The operator passively separates the muscle to expose the broken ends of fractured bone (Fig. 4).

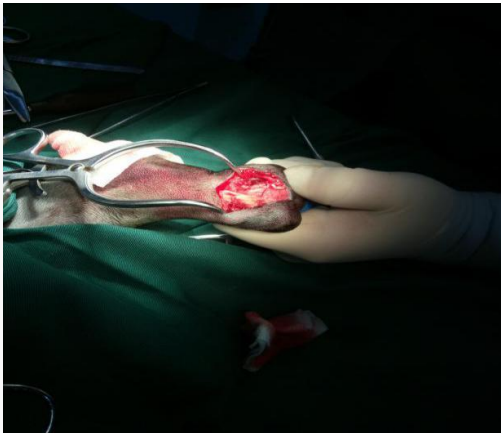
Secondly, on the oblique side of the operation towel, by pinching and pressing the salt water bottle, use sterile normal saline (a needle was inserted into the saline bottle) to repeatedly wash the surgical incision site. At the same time, check whether there are small broken bone pieces and blood clots in the affected part. If there are, clean them, and then integrate and fix the broken ends of fractured bone (Fig. 5).

Then, determine the internal fixation plate to be used. Because the fracture site is relatively special and close to the joint, we chose the 7-holes T-shaped bone plate without holes in the middle for internal fixation. Use the electric bone drill to drill the tibia at the corresponding position of the internal fixation plate holes with the help of a drill guide (Fig. 6). On the proximal side of the tibia, the drill bit was led to the proximal tibia at an angle of 15 degrees to the horizontal direction; on the distal tibia side, the drill bit was about 30 degrees to the plane of the steel nail on the proximal side, and the drill bit was led to the distal tibia at an angle of 15 degrees to the horizontal direction. Screws were led from both ends of the internal fixation plate to the middle. After the screws were led, we examined the fit degree between the plate and the tibia and the broken ends.

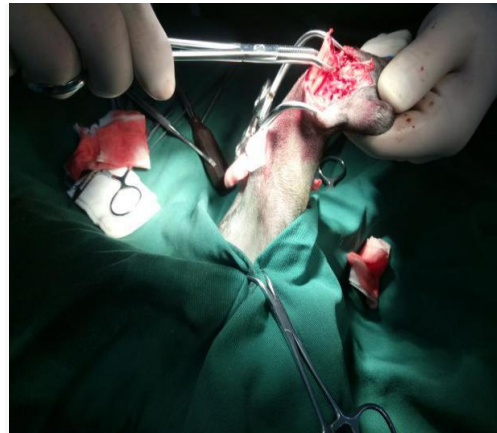
Finally, use absorbable surgical sutures to intermittently suture the periosteum and the muscle tissue that was previously bluntly dissected. Suture the skin with sterilized silk thread, smooth the incision (Fig. 7) and drop anti-inflammatory drugs, and then spray a layer of aluminum on the suture and around the suture. The operation was complete.

#### 4.4.3 After operation

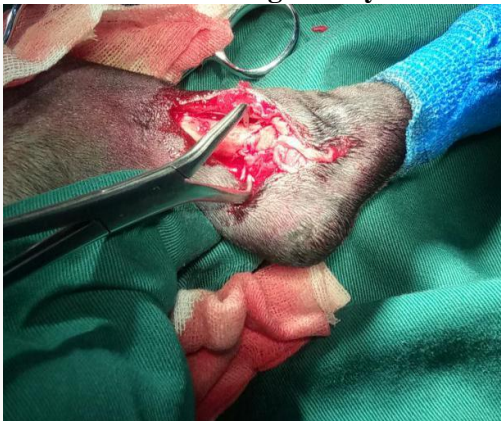After the operation, we can take two more DR images to check the operation results (Fig. 8 and Fig. 9), and analyze and evaluate the prognosis of operation.



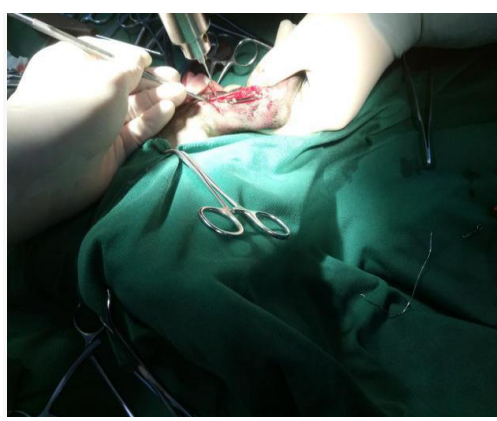
**FIGURE 3: After being bluntly dissected**



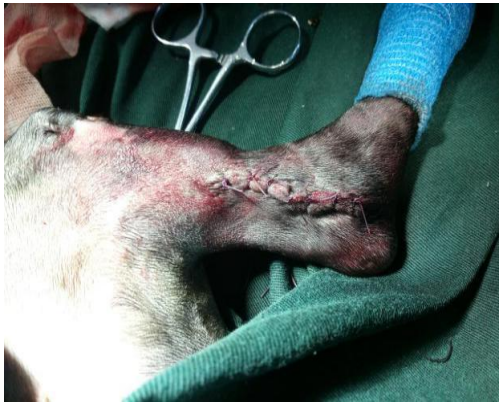**FIGURE 4: The broken ends of fractured bone**



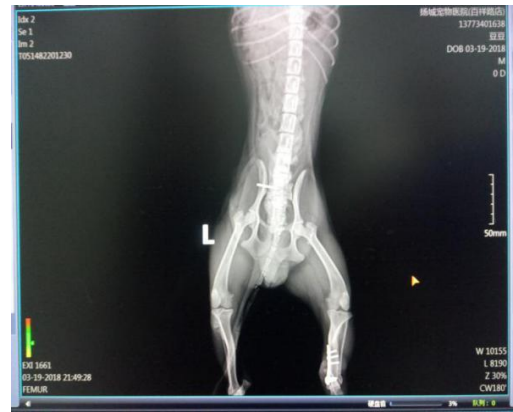**FIGURE 5: Integrate and fix the broken ends**



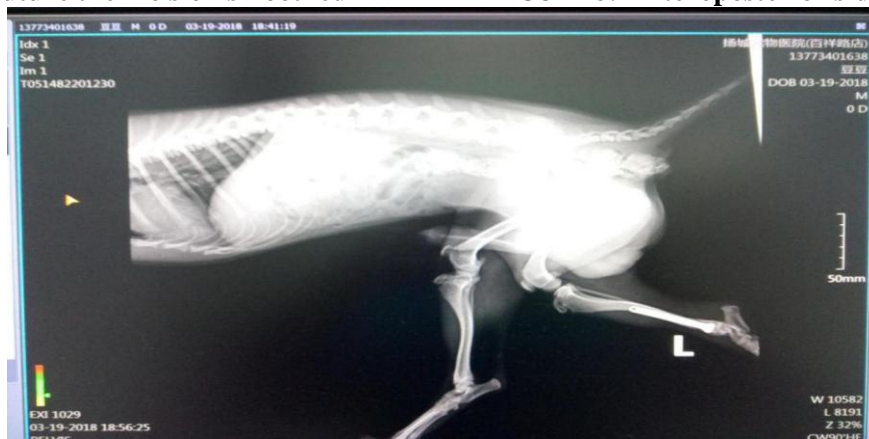**FIGURE 6: Tibia perforation**



**FIGURE 7: Suture the incision smoothed**



**FIGURE 8: Anteroposterior side after operation**



**FIGURE 9: Lateral side after operation**

## V. POSTOPERATIVE CARE

Let the dog wear Elizabethan ring, so as to prevent the dog from licking the surgical suture wound, resulting in infection of the surgical wound. Keep the dog in cages to limit its movement. It was hospitalized for a total of seven days. On the seventh day, we took out the suture and let it leave hospital. In two weeks after that, limit its exercise. For one month, the dog was prohibited from strenuous exercise. Feed high calcium food and nutritious food to help physical recovery and bone healing.

### 5.1 Daily care

Every day, use iodophor to disinfect the wound; clean the hair and scab on the wound to keep the wound dry and clean; observe whether there is infection and pus on dog's wound; drip anti-inflammatory drugs on the wound to observe the dog's eating, drinking, defecation, urination and limb movement. On the second day after the operation, the dog ate a small amount of food, but did not drink water. After a few days, the appetite gradually recovered, the water drinking became normal, and the defecation and urination returned to normal. On the third day after the operation, the left hind limb of the dog could walk gently; on the fifth day after the operation, the left hind limb of the dog, as a force supporting point, could bear the load; on the seventh day after the operation, the wound had no infection and healed well, so we took out the suture. After the suture was removed, apply erythromycin ointment to the suturing holes. On 9th day, remove the Elizabethan ring.

### 5.2 Daily anti-inflammatory

Every day, give the dog infusion for anti-inflammatory, to promote bone growth and healing and pain relief. The infusion drugs were as follows: 50ml 0.9% NaCl injection, 2ml ceftiofur; 30ml metronidazole sodium chloride injection; 30ml 0.9% NaCl injection and 2ml ossotide injection.

## VI. SUMMARY AND DISCUSSION

### 6.1 Reasons for choosing internal fixation

For this case, the stability of the fixation provided by plaster and splint were insufficient. As for external fixation, it is usually used in dogs without dislocation on the fractured ends. Fixation of plaster and splint is only suitable for some tibia and fibula fractures, and strict nursing care is needed, which may lead to poor alignment or that the broken bones are not nonunion.



## 6.2 The choice of operation time

Because of the body condition, bleeding and edema of the dog with bone fracture, it is very important to choose the right time of operation for internal fixation. Relevant medical data show that it is more appropriate to carry out operation one week after fracture. In this way, the weak dog is easy to supplement nutrition and the swelling of fracture end may disappear. However, in clinical, it is more often to carry out operation immediately after the fracture, which is conducive to the recovery of the fracture end. If the operation is carried out after 3 days, the main purpose is to eliminate the swelling of the affected part and reduce the bleeding and the interference of bleeding on the operation. However, according to the author's experience, if the operation is carried out after more than 4 days, there will be a small amount of callus formation or tissue hyperplasia at the fracture end in most cases, affecting the operation.

## 6.3 Anesthesia and aseptic operation

Good anesthesia is a necessary condition for the operation to be carried out smoothly. The sensitivity of dogs to anesthetics is different. If the anesthesia is not enough, it will directly affect the operation process. If the anesthesia is excessive, it will easily lead to the death of dogs. So anesthesia must be appropriate, so that the operation can be carried out smoothly. In addition, aseptic operation is very important, because aseptic operation can prevent the occurrence of fracture healing difficulty and healing delay. If the aseptic operation is improper, it may lead to osteomyelitis and other serious sequelae.

## 6.4 Reduce the surgical injury

In this operation, the medial incision method is used, and there are less tissues to be cut and it can easily expose the fracture ends. When opening the affected area, we should try our best to use blunt dissection to reduce muscle injury; protect the lateral saphenous vein, and according to the need of exposure the operative field, we should as far as possible avoid it or transect it after ligation, so as to protect the peripheral nerve from injury.

## 6.5 Postoperative care

After the internal fixation is completed, we can take appropriate external fixation to enhance its stability. After the operation, apply antibiotics to the whole body of the dog to prevent and control the infection; strengthen the feeding management and nutrition, and supplement vitamin A, vitamin D and calcium preparations; limit its activity for 2 weeks. After operation, X-ray film should be taken regularly to check the recovery. The dog was in its infancy, so the bone healing and growth were faster. Removed the internal fixation steel plate two months after the operation.

## ACKNOWLEDGMENT

This work is supported by "National Development and Reform Commission of China's Bio-breeding Capacity Building Project" (20150299); "Jiangsu Modern Agricultural Industrial Technology System Construction Project" (JATS2018243).

## REFERENCES

- [1] Liu Fang, Dong Haiju, Wang Mengyan. *One case of internal fixation treatment for a dog tibia and fibula fracture*. Chinese Journal of animal husbandry and veterinary medicine, 2010, 37 (6): 205-206.
- [2] Li Lin, He Jianbin. *Surgical nursing and first aid for small animals*. Shenyang: Liaoning Science and Technology Press. 2016:31-32
- [3] Long Tan, Luo Yi. *Clinical infusion therapy for small animals*. Beijing: China Agricultural Press. 2016:93-95
- [4] Xu Lyping, Chen Weiping. *Analysis of related factors and nursing countermeasures for incision infection in orthopedic surgery*. Chinese Journal of Nosocomiology. 2013,2 (03): 26-29
- [5] Yu Zezhong, Wang Ping. *Diagnosis and treatment for tibia and fibula fracture in Kunming dog*. Chinese Journal of animal husbandry and veterinary medicine. 2013,40 (04): 229-231
- [6] Zhang Binkai, Feng Zhonglan, Wang Guanglong, et al. *Internal fixation of a dog's right simultaneous anterior and posterior limb fractures*. Shanghai Journal of Animal Husbandry and Veterinary Medicine. 2015 (01): 47-49
- [7] Wu Fangqian. *Internal fixation with screws and allogeneic bone graft for the treatment of humerus collapse and fracture and shoulder subluxation*. Contemporary medicine. 2018,2 (08): 160-161
- [8] Yao Rouxin, Qian Zexiu, Huang Liquan. *Pet diagnosis and treatment*. Zhejiang animal husbandry and veterinary medicine. 2015,4(08):40-41.
- [9] Ding Xu. *Diagnosis and treatment of open fracture in Golden Retriever*. Chinese animal husbandry and veterinary abstracts. 2015,31(05):205-205.